

Overview of spontaneous Retropharyngeal Hematoma, Diagnosis, Etiological factors, and Treatment

¹Assaf Abdullah Alkatheri, ²Mohammad Mane M Alqhtani, ³Atteah Jebreel Al-abdali, ⁴Mohammed Moshabbab Abdullah Alqahtani

Abstract: This review was aim to overview the RH from different perspectives, we intended to discuss the complications and diagnosis procedures and risk factors associated with Spontaneous retropharyngeal hematoma and the treatment approaches. We conducted an electronic search of literature through several medical databases; MIDLINE/PubMed, and Emabse databases mostly for all studies concerning Spontaneous retropharyngeal hematoma, published in English language until December, 2016. The start of symptoms related to an acute retropharyngeal process in whom MR recommended a specific medical diagnosis of retropharyngeal hematoma. This potentially lethal condition can be hard to identify scientifically and by CT imaging. Retropharyngeal hematoma is an unusual disease, however might establish distant from a presenting injury and in the setting of typical coagulation and platelet function. Resultant dyspnea is an ominous indication of impending respiratory collapse and requires promptly protecting the airway. Concomitant spine injuries need to be sought and when present, might further make complex efforts at airway management. Spontaneous retropharyngeal hematoma (RH) is a rare cause of intense non-inflammatory neck swelling that may rapidly evolve to upper respiratory airway obstruction. The diagnosis is frequently postponed because of its rarity and the lack of objective indications and diagnostic lab data in the majority of cases.

Keywords: Diagnosis, Etiological factors, spontaneous retropharyngeal hematoma.

1. INTRODUCTION

Spontaneous retropharyngeal hematoma (RH) is a rare cause of intense non-inflammatory neck swelling that may rapidly evolve to upper respiratory airway obstruction. The diagnosis is frequently postponed because of its rarity and the lack of objective indications and diagnostic lab data in the majority of cases ^(1,2,3).

The classical manifestations of cervico-mediastinal hematomas are referred to as "Capp's triad" and include tracheal and esophageal compression, anterior displacement of the trachea, and subcutaneous bruising over the neck and anterior chest ^(3,5). In a few cases, the blood loss triggered complicating hypovolemic shock ^(1, 4). In cases of moderate RH, medical indications are associated to airway compression and consist of dysphagia and dysphonia, which might progress to dyspnea and upper breathing failure, without subcutaneous bruising ⁽²⁾. The systems activating hemorrhage into the retropharyngeal area are believed to consist of injury to the longus colli muscles on the anterior surface of the vertebral bodies, the anterior longitudinal ligament or the anterior muscular and spinal branches of the vertebral arteries ^(6,7,8). These injuries are most commonly connected with closed cervical neck trauma ⁽⁶⁾ and anticoagulant therapy ⁽¹⁾, however they have likewise been credited to blunt head injury, bleeding diathesis, cannulation of the internal jugular vein, arteriography, whiplash injury, foreign body intake, retropharyngeal infection, carotid artery aneurysm, carotid sinus massage, metastatic disease and can even happen spontaneously ^(8,9,10). As blood enters the retropharyngeal area, the broadening hematoma can cause tracheal compression, which may rapidly progress to severe airway blockage ^(6,7). The occurrence of respiratory tract blockage resulting from retropharyngeal hematomas is low, however its incident can be life threatening ^(6,8,10). Patients whose symptoms are suggestive of retropharyngeal hematomas call for close and often prolonged follow-up because, just like our patient, a delay can exist in between the patient's preliminary injury or signs

and the advancement of breathing distress^(7,11). Although many patients become symptomatic instantly or within hours of the advancement of the hematoma, there have been reports of patients who experienced airway obstruction as long as 5 days after developing the preliminary symptoms of respiratory tract compression^(8,9,12). Clinicians should keep a high degree of suspicion when examining patients providing with signs of air passage compression whose mechanism of injury follows those related to retropharyngeal hematomas due to the fact that these preliminary signs might progress quickly to lethal airway blockage. In particular, dyspnea should be thought about a key medical sign of a possible air passage crisis since substantial air passage compression should occur prior to a healthy patient reporting a dyspneic sensation^(7,12).

Since Spontaneous retropharyngeal hematoma (RH) is a rare condition, and there are no reviews studies discussing the concerned topic, therefore, this review was aim to overview the RH from different perspectives, we intended to discuss the complications and diagnosis procedures and risk factors associated with Spontaneous retropharyngeal hematoma and the treatment approaches.

2. METHODOLOGY

We conducted an electronic search of literature through several medical databases; MIDLINE/PubMed, and Emabse databases mostly for all studies concerning Spontaneous retropharyngeal hematoma, published in English language until December, 2016, with human subject only. Further we searched references of each identified study for more relevant articles (case reports, randomized control trials, systematic review, meta-analysis).

3. RESULTS

○ *Diagnosis of Spontaneous retropharyngeal hematoma (RH):*

Bleeding tendencies must be dealt with on an immediate basis with input from a hematologist. An especially challenging case to handle is that of a hemophilic patient with high levels of preventing antibodies to factor VIII. A current case report has highlighted the effective use of recombinant triggered factor VII in a life-threatening retropharyngeal hematoma⁽¹³⁾. and may be misdiagnosed with viral pharyngitis. The patient may be misdiagnosed with retropharyngeal abscess if a retropharyngeal mass is recognized. Many recorded causes have occurred in the context of coagulopathic states, trauma, rupture of the carotid artery, bleeding from paraesophageal veins, infection, parathyroid adenoma rupture, metastasis, angiographic procedures, and foreign body consumption^(3,4). Five cases of "spontaneous" RH, without any identifiable predisposing risk factors, have been reported; two of these cases had fatal outcomes^(1,2).

Computed tomography (CT) and MRI are used to diagnose a retropharyngeal hematoma, and close observation of prevertebral soft tissue width in lateral cervical spinal column radiograph is essential^(14,15). Penning⁽¹⁶⁾ reported that normal prevertebral soft tissue widths were 4.6 mm, 3.2 mm, 3.4 mm, and 5.1 mm at C1, C3, c2, and c4 level in the neutral position, and 14.9 mm, 15.1 mm, 13.9 mm at C5, C6, and C7 level in neutral position. Rojas et al.⁽¹⁷⁾ reported that the upper limits of normal range for thickness of prevertebral soft tissue were 8.5 mm, 6 mm, 7 mm, 18 mm, and 18 mm at C1, C2, C6, c7, and c3, respectively. The ceiling of typical variety was not determined for C4 and C5 levels due to variable position of the esophagus and larynx. Furthermore, they reported that mean prevertebral soft tissue density were 7 mm at C4 and 12.4 mm at C5 on multi-detector CT images. In our case, thickness of the prevertebral soft tissue was likewise mildly increased to 8 mm at C3 and 10.5 mm at C4 compared with these referral worths. Therefore, we believe these recommendation worths may work in early detection of underlying retropharyngeal or cervical spinal column pathology in scientific circumstances⁽¹⁷⁾.

Differential diagnosis of retropharyngeal hematoma includes retropharyngeal tendinitis and retropharyngeal infection. Retropharyngeal tendinitis is because of calcific deposits within the tendons of the longus colli muscles as in calcific deposits in calcific tendinitis of the shoulder. Radiographic findings are characteristically amorphous calcification localized anterior to C1 with associated swelling of the prevertebral (or retropharyngeal) soft tissues from C1 through C4⁽¹⁸⁾. Clinical functions are unexpected onset of serious pain in the neck and throat exacerbated by swallowing and movement of the head; this may be connected with mild fever and elevation of ESR. Pain reaches a maximum within 2-5 days then slowly subsides, generally totally within 1-2 weeks. Preliminary medical and radiologic findings in this case misguided our diagnostic impression toward retropharyngeal tendinitis. Although CT is the technique of option for verifying calcification, MRI was performed to assess both calcification and cervical disc disease in this case. Medical findings of retropharyngeal infection consist of acute to subacute onset of neck dysphagia, odynophagia, or pain; mildly raised WBC count; and low-grade fever. ESR may be slightly elevated, and there may be a recent history of upper

breathing infection or minor trauma to the head or neck ⁽¹⁹⁾. Careful history taking, looking for indications of fever, and close follow-up of lab tests are very important in differential medical diagnosis of retropharyngeal infection. Extra CT and MRI can also be helpful.

Treatment of retropharyngeal hematoma is generally to secure the respiratory tract and eliminate the hematoma. Further securement of the air passage might be required during a unique respiratory tract obstruction sign, and surgical elimination and drainage might be essential in cases highly suggestive of an infection, foreign bodies or constant hematoma growth. In cases including little hematomas, close observation may be adequate for patients with no dyspnea ⁽²⁰⁾. Muñoz et al. ⁽²¹⁾ reported that in spontaneously developed hematoma, nearly complete absorption was observed after 1 week, after they have released a case report of A 54-year-old guy without any history of preexisting neck disease presented to the emergency ward with a 1-day history of sore throat, dysphonia, and dysphagia that had its start after vomiting that the patient attributed to a fatty meal. Previous case history consisted of chronic bronchopathy due to heavy cigarette smoking. Moderate inspiratory stridor was kept in mind on decubitus position. Assessment of the oropharynx was plain, however fiberoptic evaluation of the laryngopharynx revealed considerable anterior bulging of the posterior pharyngeal wall with reddish staining but no ecchymosis ⁽²¹⁾. In addition, mild left hemilaryngeal and pharyngolaryngeal fold swelling was noted. Chest X-ray showed mild cardiomegaly. Hematologic evaluation revealed a hematocrit of 47.9%, hemoglobin of 15.9 gr/dL, and indicate corpuscular volume of 94. Leukocyte count (per mm³) was 12.700 (neutrophils, 87.5%; leukocytes, 7.0%; monocytes, 4.9%). Platelet count was 215,000/ dL. Coagulation tests revealed a prothrombin activity of 96%, typical partial-thromboplastin time, and fibrinogen of 485 mg/dL. CT of the neck (Figure 1A) ⁽²¹⁾ disclosed a midline hypoattenuating retropharyngeal collection, without peripheral enhancement, that ventrally displaced the posterior pharyngolaryngeal wall. The respiratory tract was not considerably narrowed. Eight hours later on, MR imaging was carried out (Figure 1B&E) ⁽²¹⁾. The image series revealed a retropharyngeal collection that displayed high signal on routine T1- and T2-weighted sequences. On sagittal T2-weighted fast spoiled gradient-echo sequence, concentric layers of high and low signal were shown. On the basis of the clinico-radiologic findings, a diagnosis of spontaneous retropharyngeal hematoma was suggested ⁽²¹⁾.

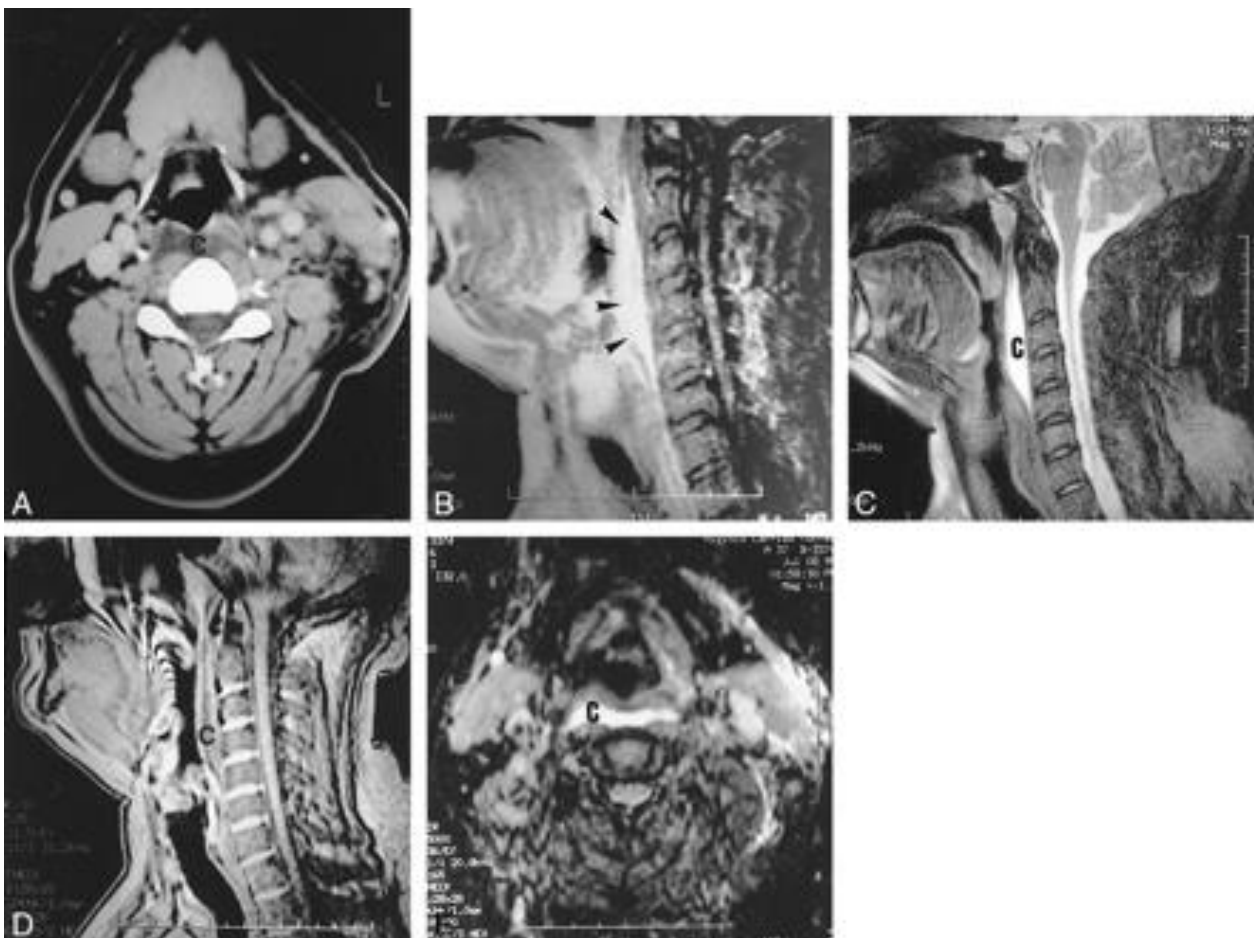


Figure 1: Retropharyngeal hematoma. in Enhanced CT scan ⁽²¹⁾

In another case report research study ⁽²²⁾ A 23-year-old male with persistent neck pain, minimal neck movement and moderate dysphagia visited our department of pain medication in spite of 3 days of treatment with analgesics and muscle relaxants prescribed by local centers. There was no particular past case history such as an injury, upper breathing infection, administration of anticoagulants or any other medical condition ⁽²²⁾. Upon physical exam, variety of neck movement was restricted with flexion 50°, extension 20°, both side lateral flexing 10° and both side rotation 15°. There was no inflammation, swelling or mass on his neck upon palpation. Examination of the oropharynx was average. Preliminary laboratory tests revealed leukocyte (WBC) count 13,610/ ul (neutrophils, 73.7%; lymphocytes, 15.7%; monocytes, 8.2%), platelet count 251,000/ dl, erythrocyte sedimentation rate (ESR) 8 (0-10) mm/hr ⁽²²⁾. Density of the prevertebral soft tissue was somewhat increased on lateral cervical spine radiograph (**Figure 2A**) ⁽²²⁾. Preliminary diagnostic impression was retropharyngeal tendinitis or cervical disc disease. Celecoxib 200 mg quote was prescribed and patient signs were mildly relieved after 2 days. Two days later on, an MRI was done exposing a prevertebral hematoma with depth 5 mm, length 5 cm dispersing from C2 to C4, and an intermediate signal in T1 and high signal in T2 image (Figure 3A, B). Follow-up lab tests showed WBC count went back to typical variety, 6,500/ uL (neutrophils, 59.9%; lymphocytes, 29.1%; monocytes, 7.2%), platelet count 294,000/ dL, ESR 8 mm/hr, and CRP 9.3 mg/L. Based upon scientific and radiologic findings, a medical diagnosis of spontaneous retropharyngeal hematoma was made. The patient was carefully followed up in the outpatient department and encouraged to instantly check out health center if symptoms such as dyspnea, irritation of neck pain or dysphagia repeated. Celecoxib 200 mg quote was continued for 3 more days, after which total remission of signs was observed in the outpatient department and follow-up lab tests revealed a return to normal variety: WBC count 6500/uL (neutrophils, 59.9%; lymphocytes, 29.1%; monocytes, 7.2%), platelet count 294,000/ dl, ESR 4 mm/hr, and CRP 3.5 mg/L. Normalization of the prevertebral soft tissue in a lateral cervical spine radiograph (**Figure 1**) and almost complete resolution of a prevertebral hematoma in follow-up T2-weight MR images (**Figure 3B**) ⁽²²⁾ were likewise kept in mind. Follow-ups at 1 week and 1 month discovered the patient stayed asymptomatic ⁽²²⁾.

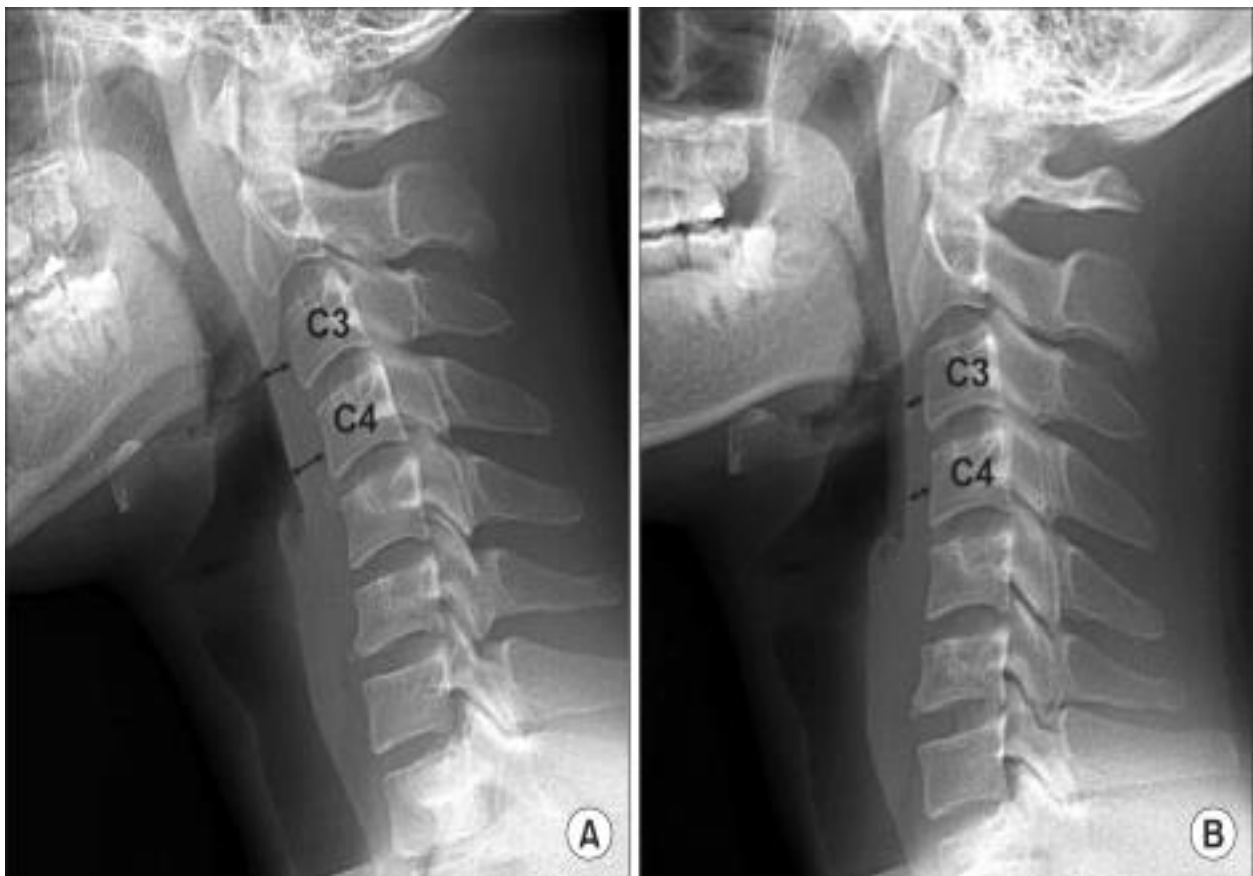


Figure 2: (A) Initial lateral cervical spine radiograph shows increased thickness of prevertebral soft tissue: 8 mm at C3 and 10.5 mm at C4. (B) At the 5-day follow-up point, lateral cervical spine radiograph shows a normalization of shadow of prevertebral space: 4.5 mm at C3 and 6 mm at C4. ⁽²³⁾

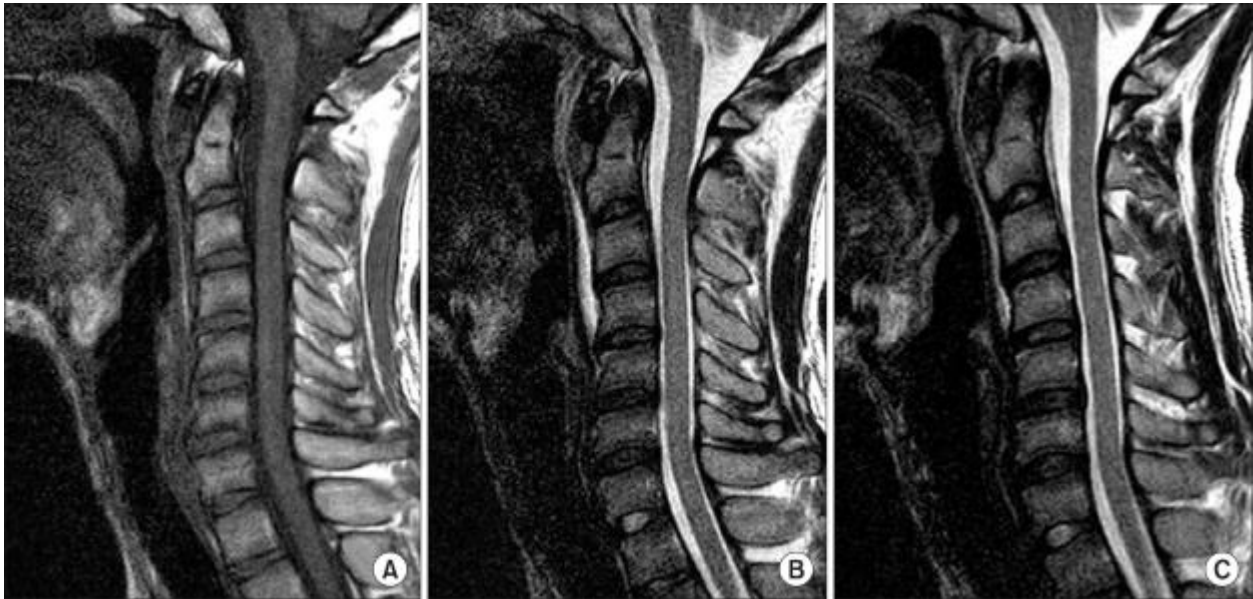


Figure 3: Magnetic resonance imaging (MRI) shows retropharyngeal hematoma. ⁽²²⁾

○ **Factors contributing in RH and treatment approach:**

Multiple etiological factors might add to RH formation and, if no cause is determined, the condition is defined as a spontaneous RH. Etiologies of RH include infection, cervical spinal column trauma, terrific vessel trauma, violent head motions, iatrogenic injury connected with heart catheterization or cerebral angiography, parathyroid adenoma hemorrhage, or foreign body intake ⁽¹⁾. Anticoagulation states ^(23,24,25,26) or hemorrhagic diathesis incline to the development of RH in humans ⁽¹⁾. Speeding up factors such as episodes of coughing, sneezing, straining and vomiting indirectly contribute to RH by increasing venous pressure and causing ruptures in the venous system. RH must be separated from abscess, arterial aneurysm, malformation or prominence of the vertebral bodies, and adenoiditis ⁽²⁷⁾.

In human medication, patients with RH secondary to coagulopathy (e.g., hemophilia, hemorrhagic diathesis, or anticoagulant treatment) present with fewer symptoms and, as soon as the medical diagnosis is made, intubation or tracheotomy is harder ⁽¹⁾. In some patients, 12 - 48 h of bleeding might precede complaints of breathing shame; nevertheless, an early, apparently indolent course can suddenly be complicated by airway blockage. Death can happen following quick development of respiratory distress from sublingual, retropharyngeal, and parapharyngeal hemorrhages ⁽¹⁾. When it comes to RH in patients on healing anti-coagulant treatment, 33 % of patients experienced sheer air passage compromise causing surgical respiratory tract management, and the mortality rate was 10 % ⁽²⁸⁾. In spontaneous RH, there is a reported death rate of up to 20 % ⁽²⁹⁾. In human patients hospitalized for cervical injury, 60 % of RH cases arise from the injury however airway blockage caused straight by the RH occurs hardly ever, in only 1.2 % of patients ^(30,31).

Treatment course may vary depending on the etiology of the hematoma, the very first step in management is establishing definitive respiratory tract control ⁽³²⁾. Steady hematoma, conservative management and observation are suggested if no air passage compromise is present and the patient has a small. These patients should be followed radiographically to guarantee complete resolution of the hematoma ⁽³²⁾. Patients with air passage compromise, however, must be managed strongly utilizing a multidisciplinary technique consisting of an experienced anesthesiologist and cosmetic surgeon prepared to carry out emerging tracheostomy if suggested. Mindful attention must be directed to any associated spine injuries which might make complex air passage management, making a tough intubation a lot more tough.

Numerous studies choose an awake nasal fiberoptic intubation method to secure our patient's air passage. This avoided the risk of respiratory tract collapse arising from conventional intravenous induction agents, although ketamine, coupled with an antisialogogue, would have been a viable alternative because it applies very little results on muscular air passage tone ⁽³³⁾. Furthermore, this approach allowed direct visualization of the patient's respiratory tract anatomy with minimal adjustment of the hematoma ^(1,32). Physicians ought to be careful to restrict thier manipulation as much as possible, for fear of hematoma rupture with resultant bleeding and worsening airway compromise ⁽³²⁾. The fiberoptic approach permitted us to keep cervical spine alignment during intubation decreasing risk of further back injury.

4. CONCLUSION

The start of symptoms related to an acute retropharyngeal process in whom MR recommended a specific medical diagnosis of retropharyngeal hematoma. This potentially lethal condition can be hard to identify scientifically and by CT imaging. Retropharyngeal hematoma is an unusual disease, however might establish distant from a presenting injury and in the setting of typical coagulation and platelet function. Resultant dyspnea is an ominous indication of impending respiratory collapse and requires promptly protecting the airway. Concomitant spine injuries need to be sought and when present, might further make complex efforts at airway management.

REFERENCES

- [1] Chin KW, Sercarz JA, Wang MB, Andrews R. Spontaneous cervical hemorrhage with near-complete airway obstruction. *Head Neck* 1998;20:350-353.
- [2] DiFrancesco RC, Escamilla JS, Sennes LU, et al. Spontaneous cervical hematoma: a report of two cases. *Ear Nose Throat J* 1999;78:168,(?) 171-175.
- [3] Al-Fallouji HK, Snow DG, Kuo MJ, Johnson PJE. Spontaneous retropharyngeal hematoma: two cases and review of the literature. *J Laryngol Otol* 1993;107:649-650
- [4] Ku P, Scott P, Kew J, van Hasselt A. Spontaneous retropharyngeal hematoma in a parathyroid adenoma. *Aust N Z J Surg* 1998;68:619-621.
- [5] Capps RB. Multiple parathyroid tumors within massive mediastinal and subcutaneous hemorrhage. *Am J Med Sci* 1954;188:800-805.
- [6] Tenofsky P, Porter S, Shaw J. Fatal airway compromise due to retropharyngeal hematoma after airbag deployment. *Am Surg.* 2000;66:692–694.
- [7] Shiratori T, Hara K, Ando N. Acute airway obstruction secondary to retropharyngeal hematoma. *J Anesth.* 2003;17:46–48. doi: 10.1007/s005400300007.
- [8] El Kettani C, Badaoui R, Lesoin FX, Le Gars D, Ossart M. Traumatic retropharyngeal hematoma necessitating emergency intubation. *Anesthesiology.* 2002;97:1645–1646. doi: 10.1097/00000542-200212000-00049.
- [9] Tsai K, Huang YC. Traumatic retropharyngeal hematoma: case report. *J Trauma.* 1999;46:715–716.
- [10] Senthuran S, Lim S, Gunning KE. Life-threatening airway obstruction caused by a retropharyngeal haematoma. *Anaesthesia.* 1999;54:670–682.
- [11] Sandooram D, Chandramohan AR, Radcliffe G. Retropharyngeal haematoma causing airway obstruction: A multidisciplinary challenge. *J Laryngol Otol.* 2000;114:706–708.
- [12] Munoz A, Fischbein N, de Vergas J, Crespo J, Alvarez-vincent J. Spontaneous retropharyngeal hematoma: Diagnosis by MR imaging. *Am J Neuroradiol.* 2001;22:1209–1211.
- [13] Macik BG, Hohneker J, Roberts HR, Griffin AM. Use of recombinant activated factor VII for treatment of a retropharyngeal hemorrhage in a hemophilic patient with a high titer inhibitor. *Am J Hematol.* 1989 Nov. 32(3):232-4.
- [14] Higa K, Hirata K, Hirota K, Nitahara K, Shono S. Retropharyngeal hematoma after stellate ganglion block: analysis of 27 patients reported in the literature. *Anesthesiology.* 2006;105:1238–1245.
- [15] Lazott LW, Ponzo JA, Puana RB, Artz KS, Ciceri DP, Culp WC., Jr Severe upper airway obstruction due to delayed retropharyngeal hematoma formation following blunt cervical trauma. *BMC Anesthesiol.* 2007;7:2.
- [16] Penning L. Prevertebral hematoma in cervical spine injury: incidence and etiologic significance. *AJR Am J Roentgenol.* 1981;136:553–561.
- [17] Rojas CA, Vermess D, Bertozzi JC, Whitlow J, Guidi C, Martinez CR. Normal thickness and appearance of the prevertebral soft tissues on multidetector CT. *AJNR Am J Neuroradiol.* 2009;30:136–141.
- [18] Haun CL. Retropharyngeal tendinitis. *AJR Am J Roentgenol.* 1978;130:1137–1140.

- [19] Eastwood JD, Hudgins PA, Malone D. Retropharyngeal effusion in acute calcific prevertebral tendinitis: diagnosis with CT and MR imaging. *AJNR Am J Neuroradiol*. 1998;19:1789–1792.
- [20] Duvillard C, Ballester M, Romanet P. Traumatic retropharyngeal hematoma: a rare and critical pathology needed for early diagnosis. *Eur Arch Otorhinolaryngol*. 2005;262:713–715.
- [21] Muñoz A, Fischbein NJ, de Vergas J, Crespo J, Alvarez-Vincent J. Spontaneous retropharyngeal hematoma: diagnosis by MR imaging. *AJNR Am J Neuroradiol*. 2001;22:1209–1211.
- [22] Kang SS, Jung SH, Kim MS, Hong SJ, Yoon YJ, Shin KM. Spontaneous Retropharyngeal Hematoma - A Case Report -. *The Korean Journal of Pain*. 2010;23(3):211-214. doi:10.3344/kjp.2010.23.3.211.
- [23] Baird KH, Fox MS. Severe sublingual and paratracheal hemorrhage in hemophilia with recovery following tracheostomy. *J Pediatr*. 1943;23:90–4. doi: 10.1016/S0022-3476(43)80045-7.
- [24] Owens DE, Calcaterra TC, Aarstad RA. Retropharyngeal haematoma. A complication of therapy with anticoagulants. *Arch Otolaryngol*. 1975;101:565–8.
- [25] Rosenbaum L, Thurman P, Krantz SB. Upper airway obstruction as a complication of oral anticoagulation therapy. *Arch Intern Med*. 1979;139:1151–3.
- [26] Mackenzie JW, Jellicoe J. Acute upper airway obstruction and spontaneous retropharyngeal haematoma in a patient with polycythaemia rubra vera. *Anaesthesia*. 1986;41:57–9. doi: 10.1111/j.1365-2044.1986.tb12705.x.
- [27] Riaño A, Bada MA, Martino R, Etayo A, Castiella JL, Palomero R. Retropharyngeal hematoma. *Rev Esp Cirug Oral y Maxilofac*. 2004;26:259–62.
- [28] Sinert R, Scalea T. Retropharyngeal and bowel hematomas in an anticoagulated patient. *Acad Emerg Med*. 1994;1:67–72. doi: 10.1111/j.1553-2712.1994.tb02804.x.
- [29] Paleri V, Maroju RS, Ali MS, Ruckley RW. Spontaneous retro- and parapharyngeal haematoma caused by intrathyroid bleed. *J Laryngol Otol*. 2002;116:854–8.
- [30] Penning L. Prevertebral hematoma in cervical spine injury. *Am J Roentgenol*. 1981;136:553–61. doi: 10.2214/ajr.136.3.553.
- [31] Kuhn JE, Graziano GP. Airway compromise as a result of retropharyngeal hematoma following cervical spine injury. *J Spinal Disord*. 1991;4:264–9.
- [32] Tsai K, Huang YC. Traumatic retropharyngeal hematoma: case report. *J Trauma*. 1999;46:715–716.
- [33] Drummond GB. Comparison of sedation with midazolam and ketamine: effects on airway muscle activity. *Br J Anaesth*. 1996;76:663–667.